

BAB V PAK FENDY

by Turnitin Instructor

Submission date: 18-May-2024 11:20AM (UTC+0700)

Submission ID: 2382387641

File name: 5._Histopathological_Condition_of...pdf (426.89K)

Word count: 3317

Character count: 17827

HISTOPATHOLOGICAL CONDITION OF MALE RAT LIVER INDUCED BY CONDENSED TANNIN EXTRACT OF BELUNTAS LEAVE

Eko Susetyarini^{1*}, Fadiatul Ainiah², Fendy Hardian Permana³

^{1,2,3}Departement of Biology Education, Faculty of Teacher Training and Education, Universtas Muhammadiyah Malang, Jl. Raya Tlogomas 246 Malang 65144. East Java, Indonesia

*Corresponding author, e-mail: susetyorini@umm.ac.id

ABSTRACT

This study at to determine the changes in liver histology of male rats after induction of condensed tannin extract of Beluntas leaves with control doses, 0.4 ml/kgBW, 2 ml/kgBW, and 3 ml/kgBW. This study is an experimental study for 14 days involving 24 samples of male rats. Parameters of histological structure changes were assessed by the scoring system for normal hepatocyte cell condition, parenchymatous degeneration, hydropic degeneration, and necrosis. One Way Anova test obtained a p value < 0.001 which means there was a significant difference in changes in the histopathological structure of liver cells significantly. Based on the Post Hoc test, it was obtained. between the control and treatment groups showed a significant difference between the control dose of 0.4 ml/kgBW, 2 ml/KgBW dose, and 3ml/KgBW dose. Meanwhile, the changes in liver histopathology between 2 ml/KgBW, and a dose of 3ml/KgBW were significantly the same.

Keywords: Antifertility, Cytotoxic, Hepatocytes, Safety, Toxicity,

INTRODUCTION

The population explosion is a major problem that is still faced by mankind today. The population always increases every year and can cause various problems (Delfita, 2014) The uncontrolled increase in population will affect the welfare of mankind itself. The reason is, the increasing number of people certainly increases the need for clothing, food, and shelter. The explosion phenomenon has shown quite serious growth in the range of 2000 to 2010 and caused disasters (Suartha, 2016)

One alternative that can be implemented to overcome the population explosion is to use antifertility drugs. With the presence of antifertility drugs, people can reduce their chances of having children. Antifertility substances can be found in various medicinal plants which are very abundant in Indonesia (Adani et al., 2017). Various synthetic antifertility drugs have been circulating in the market. However, antifertility drugs for men are not widely found. The potential to reduce the population explosion is expected to be carried out by men. There are not many male antifertility drugs found besides contraception in the form of synthetic injections. The use of synthetic drugs has higher side effects than natural drugs (Sumayyah & Salsabila, 2017) Therefore, the presence of antifertility drugs from natural compounds needs to be developed.

One of the plants that contain natural compounds that may be used as antifertility drugs is *Pluchea indica*. *Pluchea indica* is a native plant to Indonesia that has been widespread all over the majority of areas in Indonesia, with significant potency of being cultivated due to its advantages (Susetyarini et al., 2020). The tannin compounds contained in it are responsible for antifertility (Susetyarini, 2015).

According to (Susetyarini, 2011) condensed tannin extract in beluntas leaves can significantly cause a higher decrease in the number of spermatozoa. However, any antifertility drug is not expected to harm the human body.

The liver is an organ that is often used as an indicator in the selection of drug candidate safety. Histopathological examination is a microscopic examination of changes in the cell structure of the tissue using the paraffin method. Changes in the histological structure of the liver are influenced by the number and types of compounds that enter the liver, including the administration of condensed tannin extracts to an individual. The liver is responsible for the biotransformation of harmful substances into harmless substances. This process causes liver cells to be easily damaged, either in the form of cell damage or impaired liver function. (Prasetyo et al., 2019)

Several previous studies examined the effect of tannins on the fertility of male white rats. Susetyarini's research (2015) has studied condensed tannins on the decrease of spermatozoa. On the other hand, these studies have not examined the safety of tannin as an antifertility agent. Therefore, this study aimed to examine the effect of tannin on the histopathological conditions of male rats. This research needs to be done because the findings obtained can be used as a basis for researchers to ensure the safety of tannin as an antifertility drug.

METHOD

Material

The material studied in this study was beluntas (*Pleucha indica*) leaves. Beluntas leaves are cleaned and then dried to observe simplicia. Simplicia prepared as much as 5 kg.

Extraction

The chopped simplicia was extracted using the maceration method, with 96% ethanol as a solvent. Then the liquid extract from the maceration will be concentrated using a rotary evaporator to obtain a thick extract. The remaining solvent was then evaporated over a water bath to obtain a thick extract and then the test solution was prepared. A good tannin extractor is a mixture of water and an organic solvent such as methanol, ethanol and aqueous acetone 7:3 containing 0.1 ascorbic acid. The addition of ascorbic acid in acetone solvent is to minimize tannin oxidation during extraction.

Preparation of Test Animals

Research Wistar rats 3-4 months old weighing 200-250 grams as many as 24 tails obtained from the Faculty of Medicine, University of Muhammadiyah Malang (UMM) and are the result of culture. Rats that will be used are adapted to the environment for at least 1 week. Before treatment, all rats were considered to determine bodyweight to facilitate dosage adjustment.

Experiment Design and Dose Selection

Male Rats (*Ratus norvegicus*) are divided into 4 groups as above consisting of Group 1: Control, namely male rats with normal conditions and normal diet, Group 2: Dose 1 (0.4 ml) ie male rats were given a dose of 0.4 ml of tannin condensed extract for 14 days. Group 3: Dose 1 (2 ml), namely male rats were given a dose of 2 ml of tannin condensed extract for 14 days. Group 4: Dose 1 (3 ml), namely male rats were

given a dose of 4 ml of tannin condensed extract for 14 days. On day 15 the animals were operated on

Histopathology preparation and data analysis

The method of killing animals before surgery uses an ether compound inhalation agent. After presenting the test samples, the animals were dissected and then prepared by fixation using 3% formalin and preparations were made by staining the organs with Hematoxyline Eosin to determine the cytological condition and the level of damage based on observations of the liver using a scoring technique according to Maretnowati in (Ayu, *et al.*, 2020)(Table 1).

Table 1. The Level of Changes in Liver Histology in Rats

Change Rate	Score
Normal	1
Parenchymatous Degeneration	2
Hydropic degeneration	3
Necrosis	4

Tools

Histological observations using a binocular light Olympus cx-21 microscope with a magnification of 400x. Observations were made on 5 fields of view in each treatment and then the score was calculated according to the type of level of change

Safety test of condensed beluntas leaf tannins as antifertility in male white rats

Declared to be ethically appropriate in accordance 7 (seven) WHO 2011 standards. 1) Social values, 2) Scientific values, 3) Equitable assessment and benefit, 4) Risks, 5) Persuasion/Exploitation, 6) Confidentiality and privacy, and 7) Informed consent, referring to the 2016 CIOMS guidelines. This is as indicated by the fulfillment of the indicators of each standard. Ethical approval with No.E.5a/172/KEPK-UMM/VII/2021. The research protocol proposed by Eko Susetyarini as principal investigator from University of Muhammadiyah Malang

RESULTS AND DISCUSSION

The results of microscopic observations of white rats' livers from 4 groups, namely control (K), dose 1 (0.4 ml/kgBW), dose 2 (2 ml/kgBW) and dose 3 ml (3 ml/kgBW) found some tissue damage. rat liver hepatocyte cell area. The damage found included parenchymal degeneration, hydropic degeneration, and necrosis. Documented results of observations of histological changes in rat liver preparations in Hematoxylin-Eosin staining at 400x magnification can be seen in Figure 1.

Based on the observation of hepatocyte cell damage, the highest damage data was experienced by rats with dose 2 treatment with an average score of 3,426.67. The lowest damage data was experienced by the control group because they were not given any treatment, only feeding and drinking water. The liver tissue structure of the control group contained the most normal hepatocyte cells among the treatment group where the hepatocyte cells were visible, the nucleus was round in the central area and the cytoplasm was homogeneous (Januar *et al.*, 2014).

The dose group 1 (0.2 ml/kgBW) showed a predominance of hydropic degeneration level hepatocyte damage with a total score of 698, while normal hepatocytes with a score of 53, parenchymal degeneration of 318, and necrosis of

121, so it can be said that most of the hepatocyte cells were damaged at the treatment dose of 2 ml / kgBW.

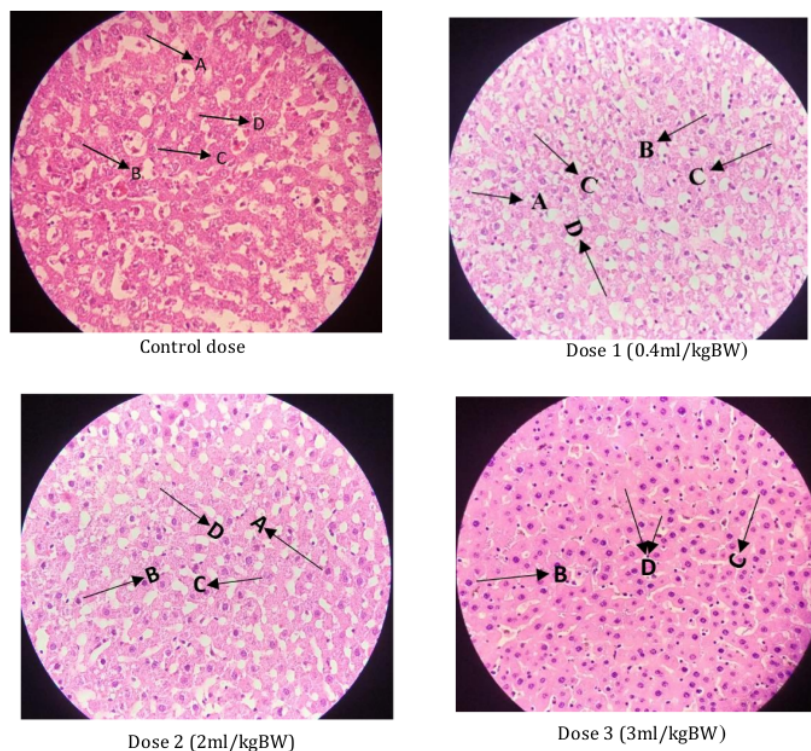


Figure 1. Liver histology of male rats after induction of condensed tannin extract. The alphabets in each treatment figure signify of hepatocyte change rate: A= Normal hepatocyte, B= Parenchymatous Degeneration, C= Hydropic degeneration, and D= Necrosis

The dose group 2 (2 ml/kgBW) was the dominant group with necrosis level hepatocyte cell damage with a total score of 523, while normal hepatocyte cells with a score of 28, parenchymal degeneration 318, and hydropic degeneration were 490, so it can be said that most of the hepatocyte cells were also damaged. at the treatment dose of 2 ml / kg.

The dose group 3 (3 ml/kgBW) was the dominant group with hydropic degeneration level hepatocyte damage with a total score of 537, while normal hepatocyte cells with a score of 10, parenchymal degeneration 194, and necrosis 459, so it can be said that most of the hepatocyte cells also suffered damage to the hepatocytes treatment dose of 4 ml/kg.

Hepatocyte cells that undergo parenchymatous degeneration/fatty degeneration show globules in the cytoplasm that push the cell nucleus to the edge and the cell size are larger than normal cells because the cells become swollen (Kadek et al., 2017). This is following the statement (Alif et al., 2021) that excessive tannin exposure can cause fatty degeneration of hepatocyte cells. Parenchymatous degeneration occurs due to failure of oxidation which results in the accumulation of water in the cytoplasm, this occurs due to disruption of protein transport that has been produced

by ribosomes (Insani *et al.*, 2015) Swelling of cells also occurs as a result of the appearance of protein deposit granules in the cytoplasm (Figure 2).

Hepatocytes that undergo hydropic degeneration have fluid-filled vacuoles that do not contain fat or glycogen such as parenchymatous degeneration with the cell nucleus in the middle (Sari *et al.*, 2018). Based on the degree of damage, hydropic degeneration is more severe than parenchymal degeneration. If the hepatocyte cells continue to be exposed to toxic stimuli, the hepatocyte cells will continue to undergo necrosis. Necrosis is permanent cell damage or cell death. The formation of necrosis is characterized by the presence of pyknotic and karyolysis. Pyknotic is characterized by shrinkage of the cell nucleus or shrinkage and karyolysis is characterized by the disappearance of the cell nucleus, so that when stained it becomes pale or faintly hollow and looks disappear. This is following the statement that most of the tannin compounds found in plants have cytotoxic properties that can trigger necrosis. Tannin compounds will later increase the production of free radicals, thereby triggering oxidative stress that will damage liver tissue (Mshelia *et al.*, 2013)




Figure 2. Hepatocyte type after treatment (400X). The alphabets in the each treatment figure signify of hepatocyte: A= Normal hepatocyte , B= Parenchymatous Degeneration, C= Hydropic degeneration, and D= Necrosis

The histological structure of the liver undergoes structural changes because the liver is very sensitive and sensitive to respond to chemicals. The liver has its own level of resistance to chemicals. Necrosis is the limit of the ability of liver cells to perform physiological functions because necrosis is permanent damage. At this stage, histopathological examination of the liver of rats was carried out after 14 days of treatment. The scoring results were analyzed for different tests using the One Way Anova test and obtained the Mean and SD can be seen in graph 1 (Figure 3).

Based on the scoring results, the mean score of changes in the histopathological structure of the rat liver increased by the increase in the dose of condensed tannin extract given. The control treatment shown in Table 2 (mean 2,182.5 and SD 136.629), dose 1 (Mean 2722.5 and SD 187.023), dose 2 (Mean 3,426.67 and SD 607.006), and dose 3 (mean 3204.17 and SD 70.669).

Table 2. Mean Score of Changes in The Histopathological Structure of The Rat Liver

Group of experiment animal (GEP)	N	n	Liver histology score mean \pm SD
Control	3	3	2,182.50 \pm 136,629
Dose 1	3	3	2,722.50 \pm 187.023
Dose 2	3	3	3,426.67 \pm 607.006
Dose 3	3	3	3,204.17 \pm 70.669

Note: N = Number of individual rats in GEP; n = Number of observed liver incision preparations

The mean liver histopathology score was tested for normality using Shapiro-Wilk and obtained a normal data distribution. The homogeneity of variances test of the mean liver histopathology scores obtained the same data variance, then

continued with the One Way Anova test. The results of the one-way ANOVA analysis showed that there was a significant difference in the histopathological changes in the 4 treatments [$F(3)]=17.142$, $p < 0.001$. Based on the Post Hoc test, it was obtained. between the control and treatment groups showed a significant difference, namely between the control dose 1, dose 2, and dose 3. Meanwhile, the changes in liver histopathology between doses 2 and 3 were significantly the same. The average results show changes in the histopathological structure of the rat liver, obtained from the process of observing microscopically through five different fields of view for the entire control group and the treated group, which can be seen shown in Figure 3.

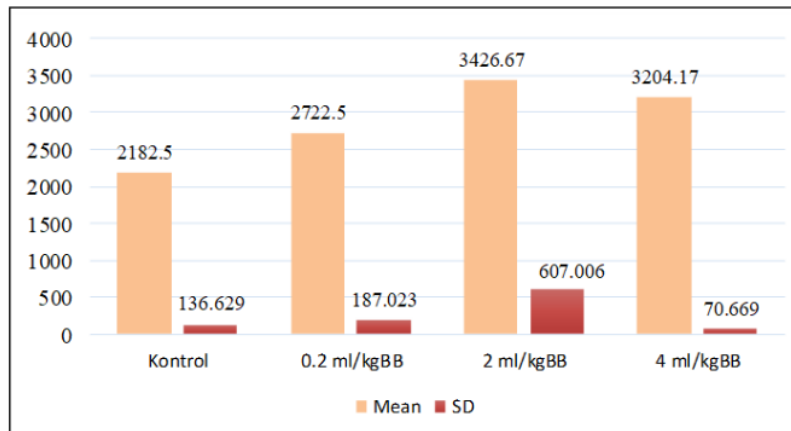


Figure 3. The mean and standard deviation of the histopathological changes of the liver

Condensed tannin compounds can be consumed but with appropriate levels and not excessive. The different characteristics of each liver histology show the sensitivity of the liver to tannin compounds. This is consistent with the statement that too many tannin compounds in plants have cytotoxic properties which can cause necrosis. Tannin compounds can increase the production of free radicals, and can cause oxidative stress which results in liver tissue being damaged (Mshelia et al., 2013) Consuming excessive doses of drugs is feared to be detrimental to health. This study has informed important findings regarding the toxicity levels of condensed tannins as natural drug candidates. However, there are some research limitations that need to be addressed. First, the microscope used in this observation still uses a light microscope. Therefore, further research using a more sophisticated microscope needs to be done.

CONCLUSIONS

In the One Way Anova test, a score of $p = 0.000$ was obtained, which means that there is a significant difference in changes in the histopathological structure of the liver cells by the three doses of condensed tannins. The histopathological structure of the liver at control doses, doses of 0.2 ml/kgBW, 2ml/KgBW and 3ml/KgBW showed significant changes, with the highest scoring value or the highest damage found at a dose of 2 ml/kgBW.

ACKNOWLEDGEMENTS

The author would like to thank the MBKM CoE team Department of Biology education, the University of Muhammadiyah Malang for facilitating the completion of this publication.

REFERENCES

- Adani, M. F., Sitasiwi, A. J., & Isdadiyanto, S. (2017). Efek Antifertilitas Ekstrak Biji Pepaya (*Carica Papaya L.*) dengan Pelarut Air terhadap Bobot Anak Mencit (*Mus Musculus L.*). *Buletin Anatomi dan Fisiologi*, 2(1), 11. <https://doi.org/10.14710/baf.2.1.2017.11-16>
- Alif, A., Syawal, H., & Riauaty, M. (2021). Histopatologi Hati dan Usus Ikan Jambal Siam (*Pangasionodon hypophthalmus*) yang Diberi Pakan Mengandung Ekstrak Daun *Rhizophora apiculata*. *Ilmu Perairan (Aquatic Science)*, 9(2), 152. <https://doi.org/10.31258/jipas.9.2.p.152-161>
- Ayu, S., Harso, W., & Jannah, M. (2020). Profil Toksikologis Ekstrak Daun Tumbuhan Baka-Baka (*Hyptis capitata Jacq.*) Pada Hati Tikus Putih (*Rattus norvegicus*). *Biocelebes*, 14(1), 10–21. <https://doi.org/10.22487/bioceb.v14i1.15082>
- Delfita, R. (2014). Potensi Antifertilitas Ekstrak Teh Hitam Pada Mencit (*Mus musculus L.*) Jantan. *Jurnal Sainstek IAIN Batusangkar*, 6(2), 181–188.
- Insani, A., Suri, S., & Berata, I. (2015). Gambaran Histopatologi Hati Tikus Putih Yang Diberikan Deksametason Dan Vitamin E. *Indonesia Medicus Veterinus*, 4(3), 228–237.
- Januar, R., Yusfiati, & Fitmawati. (2014). Struktur Mikroskopis Hati Tikus Putih (*Rattus norvegicus*) Akibat Pemberian Ekstrak Tanaman *Tristanopsis whiteana Griff.* *Jurnal Online Mahasiswa*, 1(2), 392–401.
- Kadek, N., Laksmi, N., Bagus, I., Winaya, O., Dharmawan, N. S., Fakultas, P., Hewan, K., Udayana, U., Patologi, L., Fakultas, K., Hewan, K., & Udayana, U. (2017). Gambaran Histopatologi Hati dan Ginjal Babi Landrace yang Diberi Pakan Eceng Gondok dari Perairan Tercemar Timbal (Liver And Kidney Histopatology Of Landrace Swine Given Water Hyacin From Lead Contaminated Water). *Buletin Veteriner Udayana*, 9(1), 1–8. <https://doi.org/10.24843/bulvet.2017.v09.i01.p01>
- Mshelia, I. Y., Dalori, B. M., Hamman, L. L., & Garba, S. H. (2013). Effect of The Aqueous Root Extract of *Urena lobata* (linn) on The Liver of Albino Rat. *Research Journal of Applied Sciences, Engineering and Technology*, 5(1), 1–6. <https://doi.org/10.19026/rjaset.5.5076>
- Prasetyo, Y. E., Merdana, I. M., Kardena, I. M., & Sudira, I. W. (2019). Gambaran Histopatologi Hepar Mencit yang Diberikan Ekstrak Etanol Sarang Semut. *Buletin Veteriner Udayana*, 21, 44. <https://doi.org/10.24843/bulvet.2019.v11.i01.p08>
- Sari, W. N., & Dhanardhono, T. (2018). Pengaruh Pemberian Butylated Hydroxytoluene (2,6-Di-Tert-Butyl-4-Methylphenol) Per Oral Dosis Bertingkat Terhadap Gambaran Histopatologis Ginjal. *Diponegoro Medical Journal (Jurnal Kedokteran Diponegoro)*, 7(2), 1154–1165.
- Suartha, N. (2016). Faktor-Faktor Yang Mempengaruhi Tingginya Laju Pertumbuhan Dan Implementasi Kebijakan Penduduk Di Provinsi Bali. *Piramida*, 12(1), 1–7.
- Sumayyah, S., & Salsabila, N. (2017). Obat Tradisional: Antara Khasiat dan Efek Sampingnya. *Farmasetika.Com (Online)*, 2(5), 1. <https://doi.org/10.24198/farmasetika.v2i5.16780>
- Susetyarini, E. (2011). Jumlah Sel Spermiogenesis Tikus Putih yang Diberi Tanin Daun Beluntas (*Pluchea Indica*) sebagai Sumber Belajar. *Biologi, Sains, Lingkungan*,

- Dan Pembelajarannya*, 20(5), 562-466.
<https://media.neliti.com/media/publications/175417/>
- Susetyarini, E., Wahyono, P., Latifa, R., & Nurrohman, E. (2020). The Identification of Morphological and Anatomical Structures of *Pluchea indica*. *Journal of Physics: Conference Series*, 1539(1). <https://doi.org/10.1088/1742-6596/1539/1/012001>
- Susetyarini, R. E. (2015). Aktivitas Tanin Daun Beluntas Terhadap Konsentrasi Spermatozoa Tikus Putih Jantan. *Jurnal Gamma*, 8(2), 14-20.

BAB V PAK FENDY

ORIGINALITY REPORT

9%

SIMILARITY INDEX

8%

INTERNET SOURCES

4%

PUBLICATIONS

2%

STUDENT PAPERS

PRIMARY SOURCES

1	journals.ums.ac.id Internet Source	1%
2	www.acarindex.com Internet Source	1%
3	Submitted to Academic Library Consortium Student Paper	1%
4	ijpsm.com Internet Source	1%
5	publications.inschool.id Internet Source	1%
6	Adi Sutanto, Imbang Dwi Rahayu, Wahyu Widodo, Janjira Sittiya et al. "Optimizing the Performance of the Small Intestine of Joper Chickens and KUB Chickens Using Herbal Medicine", BIO Web of Conferences, 2024 Publication	1%
7	iopscience.iop.org Internet Source	1%
8	talenta.usu.ac.id Internet Source	

1 %

9

Susetyarini, Rr. Eko. "The Level of Glutamic Acid in the Semen of Male White Rat (*Ratus Norwegicus*) after Being Treated with Tannin of *Pluchea Indica*", *Procedia Chemistry*, 2015.

Publication

1 %

10

journal.stifera.ac.id

Internet Source

1 %

11

olddrji.lbp.world

Internet Source

1 %

12

www.hindawi.com

Internet Source

1 %

Exclude quotes On

Exclude matches < 1%

Exclude bibliography On